

Endodontics

Lecture 2

Dr. Jaber Al Ibraheem

Pain Control in Endodontics

The pain reaction threshold (PRT) is defined as that point at which a person will feel the pain. With endodontic therapy hyperresponse to stimulation is significantly increased.

Factors that lower the PRT include:

- 1- Presence of pain in the beginning of treatment.
- 2- Fatigue.
- 3- Fear and anxiety.

By increase of pain sensation, blood level of catecholamine suddenly elevates with an increase in blood pressure and heart rate. This might induce fainting, angina pectoris, asthma and psychiatric reactions. To reduce the possibility of such conditions happening the anaesthesia has to be introduced slowly and in supine position.

Differential diagnosis of dental pain

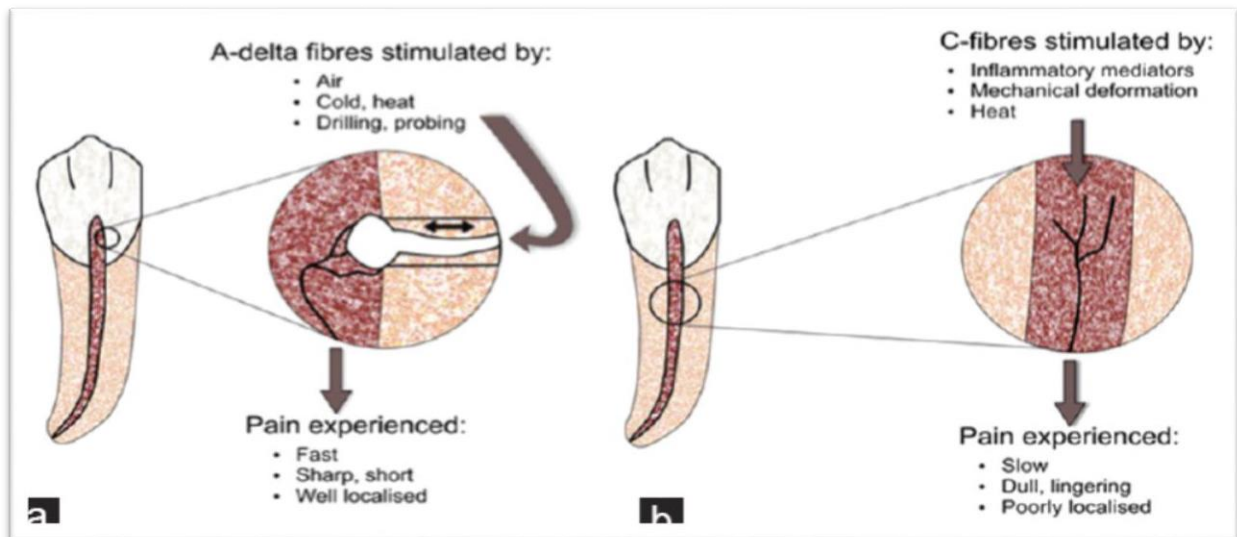
Pain in the facial region may be of different origins as:

- 1- Dental: This type is due to reversible pulpitis, irreversible pulpitis and symptomatic apical infection.
- 2- Musculoskeletal: As temporomandibular joint disease.
- 3- Neuropathic: Pain may be due trigeminal neuralgia or herpes infection.
- 4- Neurovascular conditions: As migraine.
- 5- Inflammatory conditions: As sinusitis.
- 6- Systemic disorders: As cardiac pain.
- 7- Psychogenic.

Dental Pain

A-fibres in the pulp are responsible for the sensitivity of dentine and thus for the mediation of the sharp pain induced by dentinal stimulation. Prepain sensations induced by electrical stimulation result from activation of the lowest threshold A-fibres some of which can be classified as A beta-fibres according to their conduction velocities. Therefore in reversible pulpitis the A fibres are sensitized.

Intradental C-fibres are activated only if the external stimuli reach the pulp proper. Their activation may contribute to the dull pain induced by intense thermal stimulation of the tooth and to that associated with extensive pulpal inflammation.



Local anesthesia

It is the temporary loss of sensation or pain in a certain part of the body produced by a topically applied or injected agent without depressing the level of consciousness. Prevention of pain during dental procedures eliminates fear and anxiety.

Knowledge of the anatomy prevents problems during anesthetic injection as muscle trismus, hematoma and intravascular injection.

There are 2 general types of local anesthetic chemical formulations:

1- Esters as procaine, benzocaine.

2- Amides as lidocaine, mepivacaine, prilocaine and articaine.

Local anesthetics are vasodilators, absorbed in the circulation and have a systemic effect directly to the blood plasma level. Vasoconstrictors in the local anesthetic constrict the blood vessels to lower the absorption of the local anesthetic into the blood stream to prolong the anesthetic effect in the area and decreasing the possibility of toxicity. It may be used to stop bleeding by infiltration of few drops in the bleeding area.

The condition of patients with hyperthyroidism, cardiovascular disease, diabetes and having drugs as tricyclic antidepressants and MAO inhibitors need a consultation with the physician before injection with a local anesthetic having vasoconstrictor.

If the local anesthetic is injected in an infected area, its onset will be delayed. The inflammatory process in an area of infection lowers the pH of the extracellular tissue from its normal value to 5-6 or lower. This low pH inhibits anesthetic action because little of the free base form of the anesthetic is allowed to cross into the nerve sheath to prevent conduction of nerve impulses. Inserting a needle into an active site of infection may spread the infection.

Topical anesthetic

It is effective to minimize surface discomfort of injection of the needle (2-3 mm in depth). This anesthetic is composed of benzocaine (up to 20%) or lidocaine as solution or ointment (5%) or spray (up to 10%).

Techniques for mandibular anesthesia

1- Inferior alveolar nerve block.

The site of deposition is near the mandibular foramen before the entry of the inferior alveolar nerve. It anesthetizes the mandibular teeth with the buccal and lingual soft tissues.

2- The Gow-Gates mandibular nerve block.

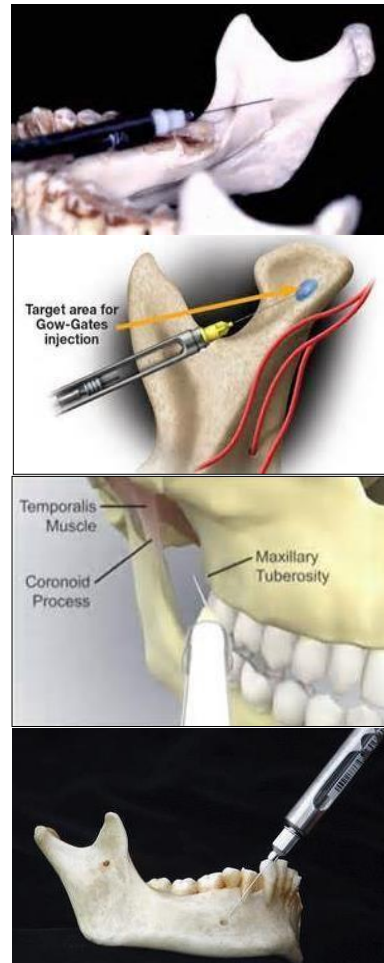
The site is the lateral aspect of the neck of the mandible condyle. It is a V3 nerve block anesthetizing all the mandibular teeth in the region with the buccal and lingual soft tissues. It provides sensory anesthesia of the buccal and mylohyoid nerve.

3- The Akinosi-Vazirani nerve block.

The site is the height of the mucogingival junction of the maxillary third molar near the maxillary tuberosity. This is used where there is limited mouth opening.

4- The Incisive nerve block.

The site is buccally between the mandibular two premolars. It provides anesthesia to the premolars and anterior teeth in the region.



Techniques for maxillary anesthesia

1- The posterior superior alveolar nerve block.

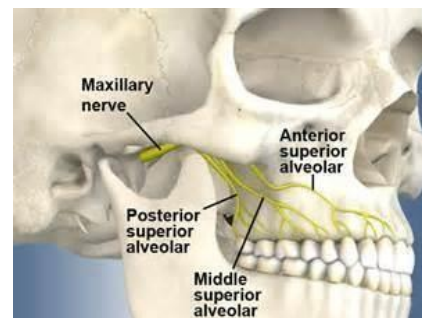
The site is in buccal fold of the maxillary 2nd molar. It anesthetizes the maxillary molars and buccal soft tissues.

2- The middle superior alveolar nerve block.

It anesthetizes the 2nd maxillary premolars and the site of injection is in the buccal fold of the premolars.

3- The anterior superior alveolar nerve block.

The site is the buccal fold of the first maxillary premolar and aimed at the infraorbital foramen. The areas anesthetized are the anterior teeth and premolars with overlying soft tissues.



Supplemental injection techniques

1- Periodontal ligament (PDL) injection.

This technique is used when no other technique can be used. The needle is inserted between the tooth and PDL with bevel of needle toward the root. Anesthetic solution of 0.2 ml is placed per root. Onset of anesthesia is immediate but duration is variable.

2- Intraosseous anesthesia.

Local anesthetic (LA) is directed into the bone surrounding the root. A small perforation is made in the cortical plate of bone with a small bur and the needle is inserted to introduce the LA.

3- Intrapulpal anesthesia.

When full anesthesia is not gained by other techniques, intrapulpal approach is used. The needle is inserted directly in the pulp and LA introduced with force. Onset is immediate.

Dental and referred pain.

Most of oral and dental pain can be traced to its source. There are cases whereby pain might be experienced away from its source as the same side but other jaw, ears, eyes and sinus. Careful diagnosis reveals the affected tooth or related anatomic structure (in non dental pain).